Oral and Maxillofacial Surgery Cases 7 (2021) 100209

Contents lists available at ScienceDirect

Oral and Maxillofacial Surgery Cases

journal homepage: www.oralandmaxillofacialsurgerycases.com

Case Report

Intraosseous venous malformation in an adolescent: Interdisciplinary concept for facial reconstruction after hemimandibulectomy, fibula free flap, and HDPE-chin reconstruction - 10 years follow up

Manfred Nilius [a,*], Frank Hölzle [b], Minou Hélène Nilius [a], Guenter Lauer [c]

[a] Londoner Bogen 6, D-44269, Dortmund, Germany
[b] Department of Oral and Maxillofacial Surgery, University Hospital of RWTH Aachen, Pauwelsstrasse 30, D- 52074, Aachen, Germany
[c] Department of Oral and Maxillofacial Surgery, University Hospital "Carl Gustav Carus", Technische Universität Dresden, Fetscherstr. 74, D-01307, Dresden, Germany

ARTICLE INFO

Keywords:
Free fibula graft
Hemimandibulectomy
High-density porous polyethylene chin
Intraosseous venous malformation
Juvenile mandibular reconstruction

ABSTRACT

Introduction: Intraosseous vascular malformations (IVM) of the jaw are rare in the adolescent. Skeleto-facial development of children is known, but facial asymmetry after hemimandibulectomy may occur in adolescence because of growth. A 12-year-old girl was performed anterior hemimandibulectomy with immediate mandibular reconstruction by fibula free flap (FFF) because of an IVM. We present an interdisciplinary treatment concept with orthodontic treatment, dental implantation, and customized high-density porous polyethylene chin augmentation on free musculocutaneous fibula reconstruction in an adolescent as a ten-year follow-up.

Aim: The presented case describes the complex interdisciplinary treatment of an adolescent suffering from the destruction of the anterior mandible caused by low-flow intraosseous venous malformation. The case report's task is to examine whether the use of customized chin implants on FFF can be a useful addition to a growth-adapted dentofacial restoration of faces in young adulthood.

Discussion: Facial growth in adolescents after tumor resection and reconstruction seems to be unpredictable. The use of customized chin-implants in children is controversial. The anticipation of the presumed adult dimensions is necessary for the correct extension. For observation of facial development, lateral-views, and CBCT, are suitable. Orienting the reconstructed mandible to correctly adjusted maxilla by orthodontic advice and early loaded implants, the development of mandible deficits can be compensated, and an average face height ratio and a mesiofacial profile anticipated.

Clinical relevance/Purpose: In line with other publications, this case shows that accompanying orthodontic treatment of the opposing maxilla after free fibula graft in the mandible is decisive for masticatory function. Immediate dental rehabilitation by fixed prosthetics on dental implants and insertion of HDPE-chin implants for facial harmonization during puberty demonstrates average growth and could be a possible concept to avoid secondary orthognathic interventions.

* Corresponding author. Londoner Bogen 6, 44269, Dortmund, Germany.
E-mail address: manfrednilius@niliusklinik.de (M. Nilius).

https://doi.org/10.1016/j.omsc.2021.100209
Received 30 November 2020; Accepted 23 January 2021
Available online 29 January 2021

The investigators hypothesized that mandibular growth-curves after sagittal hemi-mandibulectomy are mainly in the superior and posterior ramus (20%) compared to horizontal ramus (5%) mandibular angulation so that customized HDPE-chin reconstruction in adolescent should be progenic oversized to correct the horizontal deficit. The authors have reported a unique concept of orthodontic treatment, immediate loading of dental implants of the vascularized fibula, and customized chin-augmentation by evaluating angle, length, and facial profile by images of CBCT and lateral view 5 and 10 years after single step surgery.
The skeleto-facial development of growing children after hemimandibulectomy is unpredictable. The presented case describes the complex interdisciplinary treatment of an adolescent suffering from the destruction of the anterior mandible caused by intraosseous venous malformation and consecutive hemimandibulectomy. A functional oral restoration with Fibula Free Flap (FFF), orthodontic treatment, immediate loading of dental implants, and fixed bridges a juvenile facial rehabilitation demand an age-appropriate treatment plan. The case report's task is to examine whether the use of customized chin implants can be a useful addition to a growth-adapted dentofacial restoration of faces in young adulthood.

1. Introduction

Intraosseous hemangiomas of the mandible are rare and not well defined. The nomenclature proposed by Mulliken and Glowacki [1] was updated in 2014 in Melbourne by the International Society for the Study of Vascular Anomalies (ISSVA). They divide vascular anomalies into vascular neoplasms and vascular malformations and categorize vascular malformations according to their origin into capillary, venous, lymphatic, arterial, and combinations of these vessels; subclassified into high-flow and low-flow malformations [2]. For the facial skeleton, most frequently, the mandible and maxilla are affected. 0.5–1% of all intraosseous lesions are intraosseous vascular anomalies [3–7]. Among these, venous malformations are the most common anomalies [8].

Many reconstructive modalities, including autologous bone grafts and different alloplastic materials, have varying efficiency [9–14]. In children and large volume defects, surgical treatment is often indispensable. Facial asymmetry may occur in adolescence because of growth. As the growth curve rises, so does the growth of vascular malformations increase in adolescents. An interdisciplinary and age-appropriate treatment that exploits maxilla-facial growth reserves with accompanying orthodontic treatment in adolescence should be favored.

1.1. Case report

A 12-year old girl visited our clinic because of a swollen, painful mandible. The lower canines and front teeth moved. A hemangioma of the symphysis was suspected. (Fig. 1). The histopathological examination of the specimen revealed a low-flow venous malformation of 49x35 × 52mm size. The defect was reconstructed immediately by musculocutaneous microvascularized fibula-graft (fibula free flap; FFF). A removable prosthesis in the mandible, fixed on the second molars, was immediately inserted.

After one year, the lateral view after tumor resection showed a shortened and asymmetrical lower face (Fig. 2). The soft tissue covering the reconstructed chin (PoG) has deviated to the left. Mandibular angles were widened and clumsy, and the maxilla transversal collapsed. Profile analysis showed a posteriorly inclined lower face and a labial deformation of the upper incisors. The radiographic evaluation indicated a vertical deficit of approximately 40 mm between the incisors and a sagittal deficit of approx. 20 mm (see

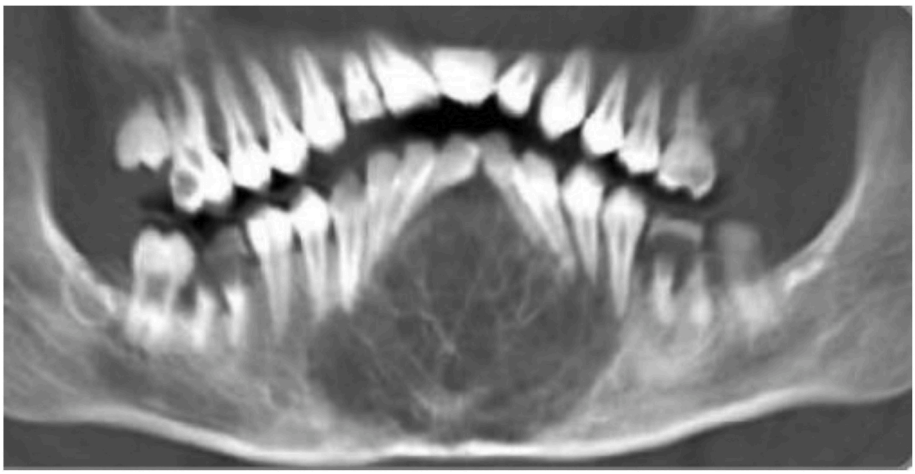

Fig. 1. Preoperative OPT of the girl at the age of 11 years.

Fig. 2. Lateral view after tumor resection and reconstruction using FFF at the age of 11 years.

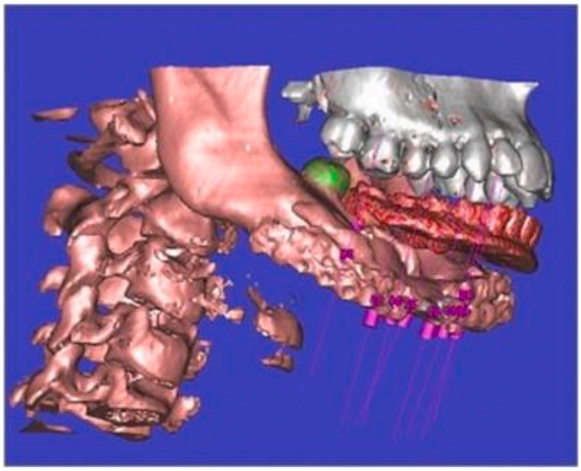

Fig. 3. CBCT for backward planning of dental implants (pink) and customized HDPE-chin Implant; (CMF®-Software; Simplant, Leiden, Belgium). Green: lower molar as reference for intercuspidation; Red: removable prosthetic denture; Grey: Maxilla.

Fig. 3).

2. Material and methods

2.1. Prosthetic and facial backward planning and implantation

Dental and facial deficits were analyzed and correlated to growth-criteria for a well-proportioned look within the preoperative situation [15–18]. For ideal positioning, backward planning helped finding the length and diameter of dental implants (CBCT: 3D-Exam, KaVo Dental GmbH, Biberach, Germany; Software Simplant Pro 10.01; Platform V10.01.6). The implants' anterior-posterior angulation was optimized regarding functional and aesthetic standards, so far as this is possible on FFF.

Fa. Stryker planned and designed the customized chin implant size using its software (Stryker GmbH & Co.KG, Duisburg, Germany; former Porex Surgical, Newnan, GA, USA) by using CBCT Scan, enface, and profile pictures of the patient before the operation (Figs. 6a and 7a). A stereolithographic model and a non-sterile template improved handling and positioning of the chin by preoperative in-vitro-operation (see Fig. 8).

For transversal maxillary expansion, orthodontic advice was inserted (Memory Expander type "N"; Forestadent, Pforzheim, Germany). Six months later, a CBCT-based bone-level template aid dental implantation by prosthetically backward planning (CMF®-

Table 1
Relative growth [%] of the remaining ascending [red] and horizontal [grey] ramus depending on age [11, 14, 17, 21 years; blue broken line]; Gonion-Angle [blue].

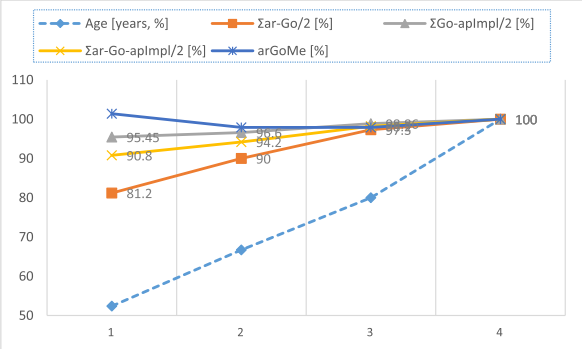

Software; Simplant, Leiden, Belgium). A submental approach allowed to remove the osteosynthesis plates fixed in the first operation. For this, the reconstructed fibula graft had an anteriorly periosteal incision to gain a pocket for the chin-implant, as recommended by Yaremchuck [19] and followed by insertion of eight dental implants (NB Replace Select Straight Groovy, NP; Length 11.5–15 mm), by bone-borne templates (Simplant, Leiden, Belgium) from an extraoral approach. After thinning the oral skin flap from 20 to 4 mm and conditioning the vestibular soft-tissue, implant-positioning was transferred to the laboratory by impression taking with open-tray copings. Extraoral scanning of the casting (Procera Scanner Mod 50, Nobel Biocare, Zurich, Switzerland) and the implant bridge's dental wax-up was possible in one day. Nobel Biocare fabricated the titanium bridge after data transfer in its CAD-CAM milling center in Sweden (Nobel Biocare, Gothenburg, Sweden). An orthodontic apparatus was activated to return maxillary collapse.

The customized chin implant was adapted to the fibula's anterior part and fixed with resorbable screws [Inion Freedom Screw ™, 2.0 × 14mm, Inion Inc., Weston, USA]. For a better aesthetic outcome, we removed the submental scar and performed a medial rotation flap.

2.2. Landmarks for long-term follow-up

We considered lateral view radiographs and CBCT made at 11, 14, 17, and 21 years for cephalometric analysis. Dental, skeletal, and profile data were compared [20–22]. Since porous ethylene-chin implants are translucence in radiographs, we landmarked for skeletal growth of the mandibular angle three points; Indicators for investigation were: Articulare (ar; the point of intersection of the dorsal contours of the articular process of the mandible and the temporals bone), Gonion (Go; lowest, posterior point of the mandible), and the apex of the most distally located dental Implant (apImpl) in the remaining mandible. We transferred the landmarks to CBCT and measured each age's distances [23].

A quotient of the following lengths and angles was determined to estimate the remaining growth of the mandible: Length of the ascending branch of the lower jaw [ar-Go], length from Gonion [Go] to the apex of the most distally located Implant [apImpl] for each side [Go-apImpl]. Length from the articulation point [ar] to the apex of the most distally located implant [apImpl] for each side [ar-apImpl] [24].

3. Results

3.1. Dental and skeletal analysis

The dental analysis is possible to a limited extent for the mandible due to reduced radiological representation of the prosthetics. The interincisal angle is standard in the beginning at 11 years (100° (102° +/- 2°) and retrudes minus 2°–98° (102° +/- 2°) at the age of 21 years. Upper incisors protruded (+14mm [OK1/A-PoG]); diff. +8mm (4+/-2°) at the age of eleven, and attenuated (+11mm [OK1/A-PoG]); diff. +5mm (4+/-2°) at the age of 21.

Immediately after augmentation (11 y), the skeletal analysis shows a slightly retrograde maxilla with SNA 79° (82° +/- 2°) and a retrograde mandible with SNB: 69° (80° +/- 2). It results in Class II deformity with ANB 7° (2+/-2°). The skeletal bite remains stable for ten years but weakens slightly as the face develops (SNA 78° (82° +/- 2°; SNB: 71° (80° +/- 2; ANB) at the age of 21 years.

At the age of eleven years, the soft tissue analysis, on the other hand, shows ANPog: 11 mm difference of +9° compared to the normal value (0° +/- 2°), a convexity in the facial profile due to the non-projection of the chin implant. Overall, this results in a brachiofacial axis angle of the face and the face height [S-Go/N–Me%: 59 (60.64%); diff. −1%]. At 21 years, the soft tissue analysis ANPog: 7 mm (0+/-2) shows a difference of +5 mm compared to the normal value (0+/-2) and convexity in the facial profile due to the radiological translucency of the chin implant. Overall, after the completion of growth (cessation), there is a brachiofacial skeletal type

with a mesofacial face height ratio [S-Go/N–Me%: 60 (60.64%); diff. 0%].

3.2. Profile analysis

The profile analysis shows protruding lip projection (11y), which remains stable until the end of growth (21y). The facial profile that was convex at the start of treatment with [Gl'-Sn-Pog': 163.3° (168.7° + −4°); (diff: 1.4°)] develops towards the end of growth to a regular profile angle of [Gl'-Sn-Pog': 170.5° (168.7° +/- 4°); (diff: 0.0°)]. The distance from the skeletal point "PoG" to the soft tissue point "PoG' "is stable for ten years! The face height ratio has changed from brachiofacial to mesiofacial in the course of growth. Gnathion (Gn') and Pogonion (PoG′) are stable throughout the observation.

3.3. CBCT analysis of ramus growth

We measured the mean distance and angle from both sides to compare the ascending and horizontal ramus growth. Reaching 100% means the end of cessation at the age of 21 years. Table 1 shows Age [years; broken blue line] and corresponding lengths [mm] of the ascending [Σar-Go/2; red] and horizontal [ΣGo-apImpl/2; grey] mandible ramus and Gonion Angle [arGoMe; blue] in [%] of growth. Age and growth of horizontal mandible [ΣGo-apImpl/2] correlate.

4. Discussion

4.1. Adolescent growth and operational intervention

To postpone defect reconstructions due to malignancy ablation in adolescence is difficult. Sharma et al. [25] recommend preserving the periosteum in place in smaller cases and reports on four children between 6 and 12 years of spontaneous, clinically, and radiographically bony regeneration within five months of resection. Genden et al. [15] recommend microvascular grafts for larger defects associated with an interruption of continuity.

It is important to use the existing growth zones for predictable chronological planning after tumor resection. Nahhas et al. [26] analyzed growth curves between the ages of 4 and 24 in their longitudinal FELS-study of 293 untreated boys and girls using polynomial Multi-Level Models (MLM). Concerning jaw growth during adolescence, Nahhas distinguishes three phases of growth: 1. The Onset of growth; 2. the cessation of growth and 3. the mean age during a maximum growth spurt (peak velocity) for boys and girls. He described the mandible and maxilla growth spurt as not significantly different in general. Each is having an earlier age of Onset [boys: 8,2y./girls: 7,1y.], later age of peak velocity [boys: 13,2y./girls: 10,9y.], and later age of cessation of growth [boys:19,9y./girls:17,1y.], as compared to the cranial base length.

During adolescence, the mandible grows more than the maxilla, both in absolute terms and relative terms (growth as a proportion of size at the cessation of adolescent growth). Also, boys experience more growth during adolescence than girls, both absolutely and relative to their size. That is, before the beginning of puberty, girls have achieved a more significant proportion of their growth than have boys. According to Kingsbury [27] and Proffit et al. [28], the "cephalocaudal growth gradient" theory (CCGG) suggests that the maxilla completes its growth before the mandible [26]. The peak velocity of mandibular length from girls (Ar-Me) is earlier (10,9y) compared to boys (13,2y). In FFF mandibular reconstructions in an 11-years girl, the opposing maxilla is already maturated and triggers the handicapped mandible growth. Immediate prosthetic rehabilitation of the compromised mandible is necessary to use this youthful growth potential.

The FFF had a removable cover denture during one-year bone healing followed by an implant-supported fixed Bridge at 12 years. One can assume that after horizontal ramus dissection, the horizontal length decrease. Buschang and Gandini [16] confirmed our findings that the ramus showed the most growth and modeling in the ramus' posterior and superior parts. Modeling changes for the corpus were smaller compared to the ascending and superior ramus. He also found that superior growth and modeling changes in the ascending ramus were related to forward rotation and inferior mandibular displacement. The condylar head as a center of mandible growth in the pediatric population confirms many authors [29–33].

In a study of 11 patients with mandibular reconstructions using a free fibular transplant in childhood, Phillips et al. [17] emphasize the importance of coordinated orthodontic-maxillofacial care. Two patients underwent orthognathic surgery after skeletal maturity and had significant complications due to the previous operation. He sums up some modifications for the original free fibula transplantation of the mandible in childhood, facilitating a bilateral sagittal split after skeletal maturity. The omission of mini plates or their inexpensive replacement with wire ligatures could be an idea suggested by Olvera-Caballero [34]. He describes the functionally stable, symmetrical, and aesthetic outcomes of seven children after mandibular ablation and reconstruction but does not say anything about dental rehabilitation.

Arboleda's study used MLM for anteroposterior mandibular length (Gn-Op) to estimate an age of cessation resulting in an age of 15.3 years for girls compared to 17.2 years [26]. Ethnic-specific craniofacial growth norms are currently unavailable. Therefore facial harmonization through an attachment chin makes sense. This fact is particularly relevant for children operated on at an early age before they begin to grow.

4.2. Chin-augmentation using high-density polyethylene implants (HDPE implants)

Using high-density porous polyethylene implants (HDPE implants, MEDPOR implants) is an indication of aesthetic-reconstructive

surgery [35–37]. In this context, functional bone replacement is not the aim here, but rather, the aesthetic contour's improvement is the indication for porous polyethylene implants. This technique allows for achieving aesthetically pleasing results and reducing operation time. However, the increased cost situation (depending on the extent in a factor of 1:10) is enormously higher.

Patients with mandibulo-maxillary tumors or defects, presenting extensive facial deformities in sagittal, horizontal, and vertical dimensions need prospective treatment planning. A bone graft is still the golden standard for facial reconstructive surgery [38]. Here, volume-stable calvary transplants, in particular, prove to be superior to iliac crest transplants as donors. However, bone grafts, especially those from the cranial area, are very difficult to contour and customarily preferred in the area of orbital reconstruction [39–41]. They often lead to malpositions and, subsequently, inadequate resorptions. In addition to orbital transplants, onlay augmentations in the alveolar ridge area, especially in the maxilla, show a high resorption potential. Those in the mandibular area often sequester due to insufficient soft tissue coverage. Facial contouring using autologous bone graft in adolescents is still non-precise. Even growing effects and resorption seem to be unpredictable in fibula graft in pediatric patients [30]. When choosing a suitable donor bone in limited amounts, the second intervention's increased morbidity on the donor site is a potential disadvantage.

In terms of their availability, handling, and volume stability, implants made of porous polyethylene are the ideal Implant for facial surgery's aesthetic-reconstructive sector [42–44]. Alternative materials to HDPE implants are titanium, ceramic, or bioactive glass components [45]. Such implant materials can be prefabricated individually and reduce the foreign body reaction [39]. However, compared to HDPE implants, the range of indications is limited due to haptic properties and the lower adjustment options through contouring. Prefabricated PEEK implants compensate for this deficit but lead to a foreign body reaction [46,47]. There are numerous publications on the use of PE implants in children as part of microtia treatment [19,36,43,48,49,49–52]. However, there is a lack of studies on the long-term stability of HDPE implants. The present case shows sufficient biostability for a minimum of ten years.

4.3. Healing and risk of HDPE implants

The infection rate of HDPE is less than 10%. Infections are particularly evident in the early healing phase and during exposure or inadequate soft tissue coverage. HDPE implants are of constant volume and show fibrovascular healing behavior [19]. Animal studies also show volume stability in functionally loaded tissue. In animal studies, after a healing time of 6 months, Vollkommer showed no (60%) or only a slight acute inflammation (40%) and 100% fibrovascular obliteration with common chronic signs of infection. An immunological reaction, however, was not found [37].

Porous polyethylene implants are attached to the underlying bone with osteosynthesis screws fixed and show good positional stability. Macroscopically, there is a slight fibrous capsule formation. The histological results indicate a complete penetration of connective tissue through the implants' interconnecting pores [53]. Tark et al. [54] examined HDPE-Implants in direct contact with bone and did not find osteogenetic activity after reapproach from 24 months.

In summary, the number of giant cells decreased depending on the length of time the Implant is in the body, increasing the length of stay. Some Authors describe this phenomenon as a foreign body reaction with less and less intensity. Romano et al. [55] see dimensional stability and minor degradation of the material in the excellent biocompatibility and firm structure of PE implants after fibrovascular integration [41].

Various authors attach particular importance to the following aspects to avert intraoperative operative difficulties. The use of computer-aided design/computer-aided manufacturing (CAD/CAM) techniques has facilitated the rapid and precise construction of customized implants [45]. For HDPE-standard chin-implants, an appropriate tissue pocket size and subperiosteal dissection are recommended [46,56,57]. Some authors focus on the location of the fixation of the implant and screw placement, especially for lateral mandibular angle implants, as these implants tend to rotate and vertical and horizontal displacement [58]. Yaremchuk [19], on the other hand, favored a broad subperiosteal exposure of the area to be augmented, as this would enable accurate positioning of the Implant and tension-free closure.

Due to its large, open-pored surface properties, porous polyethylene seems to have an unfavorable prerequisite for bacterial colonization. There is increasing prophylaxis against infections due to the transplant's complete vascularization during the healing phase [53]. According to the literature, the transplant's complete vascularization depends on the size and can take up to a few months.

In the case of contradicting literature, the authors recommend the antibiotic impregnation of the Implant (e.g., with metronidazole solution) as part of the "implant venting" immediately before the implementation of the Implant. By using large-volume syringes, size-depending implant-venting is possible without any problems. Special attention must be paid to the soft tissue coverage during implantation, as the implant exposure usually leads to explantation.

In the retrospective study by Yaremchuk published in 2003 [19], 370 implants for facial augmentation placed in 162 patients. 10% of the cases required secondary surgery. The most common causes: acute infections (2%), late infections (1%), and recontouring measures (7%). A review of the extensive literature results shows the worst results with an increased rate of complications, especially when using implants in syndromic diseases with multiple previous operations and augmentative operations on the maxilla, nose, and ear. Many suspect the cause to be primarily related to the amount of soft tissue available for implant coverage. Menderes et al. [35] placed 83 implants for craniofacial reconstruction. Their study showed an increased risk of early and late exposure if the HDPE-Implant was placed directly under the skin instead directly subperiostal to the bone.

5. Conclusion

An essential disadvantage of Medpor implants is their invisibility in radiographic studies because the HDPE- Implant shows no contrast [42]. The representation of titanium-reinforced HDPE implants, however, works well.

Fig. 4. Extraoral approach for mentoplasty and fixation of a customized HDPE-chin implant to the FFF's anterior part.

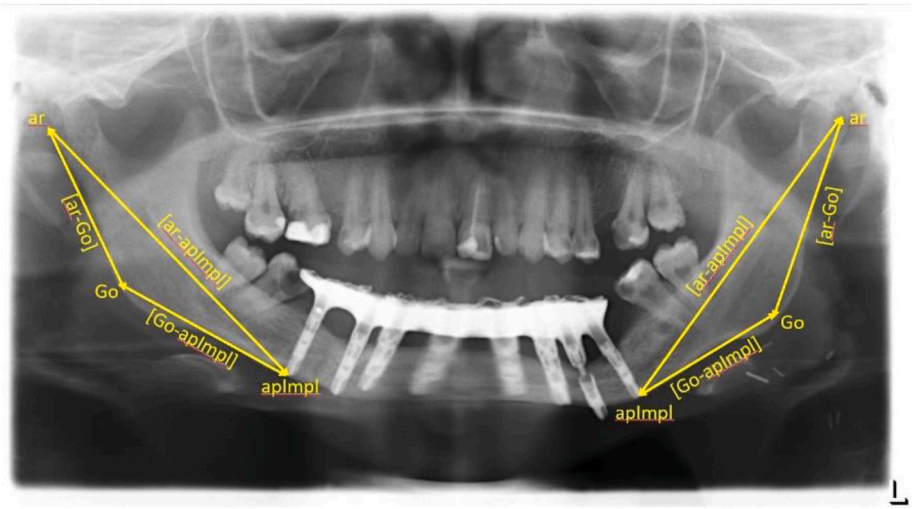

Fig. 5. OPT with three landmarks (yellow) and three distances for remaining mandible growth: Articulare (ar); Gonion (Go); Apex of the most distally located dental Implant (apImpl).

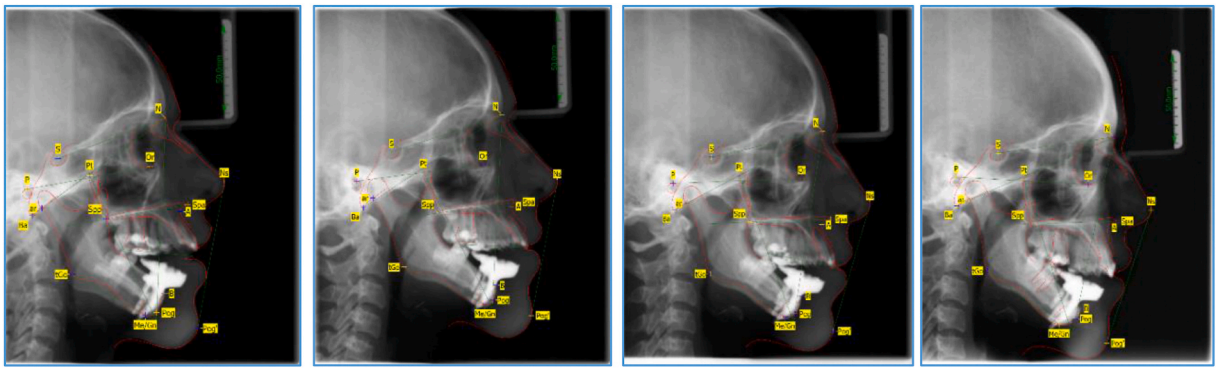

Fig. 6. 6a, 6b, 6c, 6d: The postoperative lateral-views document for ten years. The pictures show the lower face's projection with the chin implant between 11 and 21 years (Fig. 6a 11y; Fig. 6b 14y, Fig. 6c 17y, and Fig. 6d 21 years).

Long-term follow-up (10 years) showed a moderate relapse from PoG to PoG′ parallel to the mandibular axis. That makes advancement genioplasty a predictable method in the context of a hemimandibuloectomy and can help compensate for vertical and sagittal deficits in childhood. For the upper jaw's skeletal growth, accompanying orthodontic treatment of the lower jaw's masticatory restoration is necessary. Using dental and facial implants together in one operation is an option for full-face makeover. Due to CBCT-

Fig. 7. 7a, 7b, 7c, 7d: Clinical situation before (7a, 11y) and after dental and facial implantation (7b, 7c, 7d) at 14, 17, and 21 years.

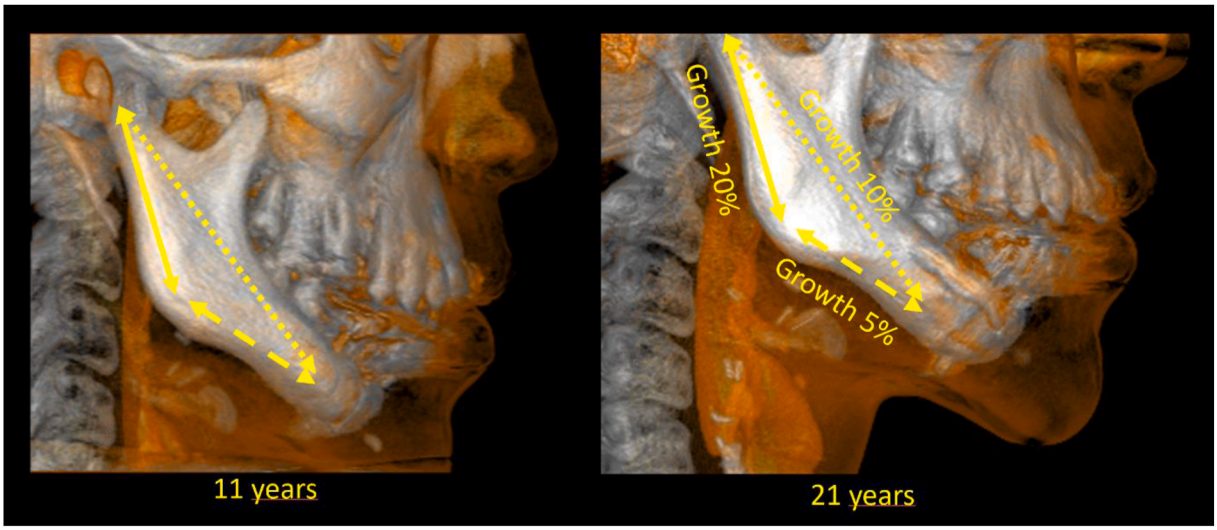

Fig. 8. Growth of mandibular ramus [%] from 11 to 21 years after hemimandibulectomy and reconstruction with FFF, dental implants, and customized HDPE-Chin.

analysis, computer-assisted surgery, we inserted the dental implants safely with bicortical contact (Fig. 4). The accuracy of the Procera® -implant Bridge based on eight implants was accurate for immediate prosthetic loading. The height of 42 mm for prosthetic abutments was necessary due to intermaxillary distance. One Implant (region 34) dislocated because the screwdriver was too short (Fig. 5). This Implant was immediately in front of the fibula, and behind the HDPE implant, it left in dislocation. Functional oral reconstruction, mastication, and aesthetic restoration (lip bumping) were acceptable.

The porous HDPE alloplastic implant has a low incidence of infection, excellent cosmetic results, and is an acceptable alternative to existing alloplastic materials. It reduces operating time and cost, avoids a second bone grafting procedure, improves the aesthetic outcome, and is beneficial for the patient and the dentist. After 5 and 10 years, the follow-up concludes that the implementation of oversized chin implants in anterior hemimandibulectomy and microvascular reconstruction in childhood allows the growth reserves known as “cephalocaudal growth gradient; CCGG” [27] in the jaw’s angle in the ascending branch of the mandible to enable facial development following the norm.

Patients consent

The patient gave written consent for publication. The patient gave written consent for publication. The author ensure that the work described has been carried out in accordance with The Code of Ethics of the World Medical Association (Declaration of Helsinki). The manuscript is in line with the Recommendations for the Conduct, Reporting, Editing and Publication of Scholarly Work in Medical Journals and aim for the inclusion of representative human populations (sex, age and ethnicity) as per those recommendations.

Declaration of competing interest

The authors declare that they have no known competing financial interests or personal relationships that could have appeared to influence the work reported in this paper.

Acknowledgments

Funding: This research did not receive any specific grant from funding agencies in the public, commercial, or not-for-profit sectors.

Abbreviations

apImpl	Apex of the most distally located dental Implant in the remaining mandible
Ar	Articulare; the point of intersection of the dorsal contours of the articular process of the mandible and the temporals bone)
CBCT	Conebeam Computer tomography
CCGG	cephalocaudal growth gradient
FFF	Fibula Free Flap
HDPE	high-density porous polyethylene implants
Go	Gonion; lowest, posterior point of the mandible
MLM	Multi-Level Model
PoG	Softtissue pogonium

References

[1] Mulliken JB, Glowacki J. Hemangiomas and vascular malformations in infants and children: a classification based on endothelial characteristics. Plast Reconstr Surg 1982 Mar;69(3):412–22. https://doi.org/10.1097/00006534-198203000-00002.
[2] North PE. Pediatric vascular tumors and malformations. Surg Pathol Clin 2010 Sept;3(3):455–94. https://doi.org/10.1016/j.path.2010.07.002.
[3] Perugini M, Renzi G, Gasparini G, Cerulli G, Becelli R. Intraosseous hemangioma of the maxillofacial district: clinical analysis and surgical treatment in 10 consecutive patients. J Craniofac Surg 2004 Nov;15(6):980–5. https://doi.org/10.1097/00001665-200411000-00018.
[4] Alves S, Junqueira JL, de Oliveira EM, Pieri SS, de Magalhães MH, Dos Santos Pinto Jr D, Mantesso A. Condylar hemangioma: report of a case and review of the literature. Oral Surg Oral Med Oral Pathol Oral Radiol Endod 2006 Nov;102(5):e23–7. https://doi.org/10.1016/j.tripleo.2006.04.004. Epub 2006 Sep. 7.
[5] Srinivasan B, Ethunandan M, Van der Horst C, Markus AF. Intraosseous 'haemangioma' of the zygoma: more appropriately termed a venous malformation. Int J Oral Maxillofac Surg 2009 Oct;38(10):1066–70. https://doi.org/10.1016/j.ijom.2009.05.010.
[6] Aldridge E, Cunningham Jr LL, Gal TJ, Yepes JF, Abadi BJ. Intraosseous venous malformation of the mandible: a review on interdisciplinary differences in diagnostic nomenclature for vascular anomalies in bone and report of a case. J Oral Maxillofac Surg 2012 Feb;70(2):331–9. https://doi.org/10.1016/j.joms.2011.03.013.
[7] Theologie-Lygidahis N, Schoinohoriti O, Tzermpos F, Christopolous P, Iatrou I. Management of intraosseous vascular malformations of the jaw in children and adolescent: report of 6 cases and literature review. J Oral Maxillofax Res 2015 Apri-Jun;6(2):e 5. https://doi.org/10.5037/jomr.2015.6205.
[8] Colletti G, Frigerio A, Giovanditto F, Biglioli F, Chiapasco M, Grimmer JF. Surgical treatment of vascular malformations of the facial bones. J Oral Maxillofac Surg 2014 Jul;72(7):1326.e1. https://doi.org/10.1016/j.joms.2014.02.012.
[9] Persky MS, Yoo HJ, Berenstein A. Management of vascular malformations of the mandible and maxilla. Laryngoscope 2003 Nov;113(11):1885–92. https://doi.org/10.1097/00005537-200311000-00005.
[10] Oliveira GG, García-Rozado A, Rey RL. Intraosseous mandibular hemangioma. A case report and review of the literature. Med Oral Patol Oral Cir Bucal 2008 Aug 1;13(8):E496–8.
[11] Liu D, Ma X, Zhao F, Zhang J. Intraosseous embolotherapy of central arteriovenous malformations in the jaw: long-term experience with 8 cases. J Oral Maxillofac Surg 2009 Nov;67(11):2380–7. https://doi.org/10.1016/j.joms.2009.04.088.
[12] Lee J, Sung HM, Jang JD, Park YW, Min SK, Kim EC. Successful reconstruction of 15-cm segmental defects by bone marrow stem cells and resected autogenous bone graft in central hemangioma. J Oral Maxillofac Surg 2010 Jan;68(1):188–94. https://doi.org/10.1016/j.joms.2009.08.031.
[13] Lemound J, Brachvogel P, Götz F, Rücker M, Gellrich NC, Eckardt A. Treatment of mandibular high-flow vascular malformations: report of 2 cases. J Oral Maxillofac Surg 2011 Jul;69(7):1956–66. https://doi.org/10.1016/j.joms.2010.09.013. Epub 2011 Jan 8.
[14] Theologie-Lygidakis N, Schoinohoriti OK, Tzerbos F, Iatrou I. Surgical management of head and neck vascular anomalies in children: a retrospective analysis of 42 patients. Oral Surg Oral Med Oral Pathol Oral Radiol 2014 Jan;117(1):e22–31. https://doi.org/10.1016/j.oooo.2012.02.039. Epub 2012 Aug 24.
[15] Genden EM, Buchbinder D, Chaplin JM, Lueg E, Funk GF, Urken ML. Reconstruction of the pediatric maxilla and mandible. Arch Otolaryngol Head Neck Surg 2000;126(3):293–300. https://doi.org/10.1001/archotol.126.3.293.
[16] Buschang PH, Gandini LG. Mandibular skeletal growth and modelling between 10 and 15 years of age. EJO (Eur J Orthod) 2002;24(1):69–79. https://doi.org/10.1093/ejo/24.1.69.
[17] Phillips JH, Rechner B, Tompson BD. Mandibular growth following reconstruction using a free fibula graft in the pediatric facial skeleton. Plast Reconstr Surg 2005;116(2):419–24. https://doi.org/10.1097/01.prs.0000172677.71629.10.
[18] Nilius M, Anastase J, Goeken R, Zahn T, Nilius MO, Gherbali I. Aesthetic and functional rehabilitation of the face using dental and facial implants. Int Post J Dent Oral Med 2007;9(2):364.
[19] Yaremchuk MJ. Facial skeletal reconstruction using porous polyethylene implants. Plast Reconstr Surg 2003;111(6):1818–27. https://doi.org/10.1097/01.PRS.0000056866.80665.7A.
[20] Legan HL, Burstone CJ. Soft tissue cephalometric analysis for orthognathic surgery. J Oral Surg 1980;38(10):744 51. PMID:6932485.
[21] Chen YJ, Chen SK, Yao JCC, Chang HF. The effects of differences in landmark identification on the cephalometric measurements in traditional versus digitized cephalometry. Angle Orthod 2004;74(2):155 61. https://doi.org/10.1043/0003-3219(2004)074<0155:TEODIL>2.0.CO;2.
[22] Mousavi SM, Ghorani PS, Deilamani A, Rakhsan V. Effects of laterality on esthetic preferences of orthodontists, maxillofacial surgeons, and laypeople regarding the lip position and facial convexity: a psychometric clinical trial. Oral Maxillofac Surg 2019;23(4):439–51. https://doi.org/10.1007/s10006-019-00795-w.
[23] Bajaj K, Rathee P, Jain P, Ranwar VR. Comparison of the reliability of anatomic landmarks based on PA cephalometric radiographs and 3D CT scans in patients with facial asymmetry. Int J Clin Pediatr Dent 2011;4(3):213 23. https://doi.org/10.5005/jp-journals-10005-1112. Epub 2011 Apr 15.

[24] Leonardi R, Annunziata A, Caltabiano M. Landmark identification error in posteroanterior cephalometric radiography. A systematic review. Angle Orthod 2008; 78(4):761 5. https://doi.org/10.2319/0003-3219(2008)078[0761:LIEIPC]2.0.CO;2.
[25] Sharma P, Williams R, Monaghan A. Spontaneous mandibular regeneration: another option for mandibular reconstruction in children? Br J Oral Maxillofac Surg 2013;51(5):e63–6. https://doi.org/10.1016/j.bjoms.2012.04.255.
[26] Nahhas R, Ramzi W, Valiathan S, Richard J. Variation in timing, duration, intensity, and direction of adolescent growth in the mandible, maxilla, and cranial base: the fels longitudinal study. Anat Rec 2014;297:1195–207. https://doi.org/10.1002/ar.22918.
[27] Kingsbury BF. The significance of the so-called law of cephalocaudal differential growth. Anat Rec 1924;27:305–21. https://doi.org/10.1002/ar.1090270511.
[28] Proffit WR, Fields Jr HW, Sarver DM. Contemporary orthodontics. fifth ed. St. Louis, MO: Elsevier Mosby; 2012. p. 341–67.
[29] Nahabedian MY, Tufaro A, Manson PN. Improved mandible function after hemimandibulectomy, condylar head preservation, and vascularized fibular reconstruction. Ann Plast Surg 2001;46(5):506–10. https://doi.org/10.1097/00000637-200105000-00009.
[30] Crosby MA, Martin JW, Robb GL, Chang DW. Pediatric mandibular reconstruction using a vascularized fibula flap. Head Neck 2008;30(3):311–9. https://doi.org/10.1002/hed.20695.
[31] Rashid M, Tamimy MS, Ehtesham-ul-Haq, Sarwar SR, Rizvi STA. Benign paediatric mandibular tumours: experience in reconstruction using vascularised fibula. J Plast Reconstr Aesthetic Surg 2012;65(12):e325–31. https://doi.org/10.1016/j.bjps.2012.07.006.
[32] Faria JCM, Batista BN, Sennes LU, Longo MVL, Danila AH, Ferreira MC. Mandibular reconstruction with a fibular osteocutaneous free flap in an 8-month-old girl with a 12-year follow-up. Microsurgery 2014;34(1):51–3. https://doi.org/10.1002/micr.22136.
[33] Castellon L, Jerez D, Mayorga J, Fuenzalida C. Remodeling of costochondral graft after mandibular reconstruction. J Oral Maxillofac Surg 2017;75(1):226.e1–7. https://doi.org/10.1016/j.joms.2016.09.012.
[34] Olvera-Caballero C. Mandibular reconstruction in children. Microsurgery 2000;20(4):158–61. https://doi.org/10.1002/1098-2752(2000)20:4.
[35] Menderes A, Baytekin C, Topcu A, Yilmaz M, Barutcu A. Craniofacial reconstruction with high-density porous polyethylene implants. J Craniofac Surg 2004;15: 719 24. https://doi.org/10.4103/ams.ams_245_18.
[36] Romo III T, Reitzen SD. Aesthetic microtia reconstruction with Medpor. Facial Plast Surg 2008;24(1):120–8. https://doi.org/10.1055/s-2008-1037453.
[37] Niechajev I. Facial reconstruction using porous high-density polyethylene (Medpor): long-term results. Aesthetic Plast Surg 2012;36(4):917–27. https://doi.org/10.1007/s00266-012-9911-4.
[38] Ram H, Singh RK, Mohammad S, Gupta AK. Efficacy of Iliac crest vs. Medpor in orbital floor reconstruction. J Maxillofac Oral Surg 2010;9(2):134 41. https://doi.org/10.1007/s12663-010-0047-2.
[39] Gander T, Essig H, Metzler P, Lindhorst D, Dubois L, Rucker M, Schumann P. Patient specific implants (psi) in reconstruction of orbital floor and wall fractures. J Cranio-Maxillo-Fac Surg 2015;43(1):126–30. https://doi.org/10.1016/j.jcms.2014.10.024.
[40] Kludt NA, Vu H. Auricular reconstruction with prolonged tissue expansion and porous polyethylene implants. Ann Plast Surg 2014;72(Suppl 1):14–7. https://doi.org/10.1097/SAP.0000000000000178.
[41] Kshitij A, Rajesh B, Dhirawani S, Singha S, Agrawal A. High-density polyethylene material versus autogenous grafts in craniofacial augmentation procedures. Ann Maxillofac Surg 2019;9(1):10–4. https://doi.org/10.4103/ams.ams_245_18.
[42] Gosau M, Schiel S, Draenert GF, Ihrler S, Mast G, Ehrenfeld M. Craniofacial augmentation with porous polyethylene implants (Medpor): first clinical results. Mund-, Kiefer- Gesichtschirurgie 2006;10:178 84.
[43] Berghaus A, Stelter K, Naumann A, Hempel JM. Ear reconstruction with porous polyethylene implants. Adv Oto-Rhino-Laryngol 2010;68:53–64. https://doi.org/10.1159/000314562.
[44] Ali K, Trost JG, Truong TA, Harshbarger RJ. Total ear reconstruction using porous polyethylene. Semin Plast Surg 2017;31(3):45–56. https://doi.org/10.1055/s-0037-1604261. ISSN 1535-2188.
[45] Tsouknidas A, Maropoulos S, Savvakis S, Michailidis N. FEM assisted evaluation of PMMA and Ti6Al4V as materials for cranioplasty resulting mechanical behaviour and the neurocranial protection. Bio Med Mater Eng 2011;21:139 47. https://doi.org/10.3233/BME-2011-0663.
[46] Yang P, Yang Q, Liu T, Liu T, Zeng J, Bi B, Zhou Y, Guo Y, Chen L. A modified technique for expanded polytetrafluoroethylene shaping in chin augmentation: parallel groove carving technique. J Craniofac Surg 2015;26(2):e146–8. https://doi.org/10.1097/SCS.0000000000001382.
[47] Stratton-Powell AA, Pasko KM, Brockett CL, Tipper JL. The biologic response to polyetheretherketone (peek) wear particles in total joint replacement: a systematic review. Clin Orthop Relat Res 2016;474(11):2394–404. https://doi.org/10.1007/s11999-016-4976-z.
[48] Cronin TD. Use of a silastic frame for total and subtotal reconstruction of the external ear: a preliminary report. Plast Reconstr Surg 1966;37(5):399–405. https://doi.org/10.1097/00006534-196605000-00003.
[49] Thorne CH, Brecht LE, Bradley JP, Levine JP, Hammerschlag P, Longaker MT. Auricular reconstruction: indications for autogenous and prosthetic techniques. Plast Reconstr Surg 2001;107(5):1241–52. https://doi.org/10.1097/00006534-200104150-00024.
[50] Storck K, Staudenmaier R, Buchberger M, Strenger T, Kreutzer K, von Bomhard A, Sstark T. Total reconstruction of the auricle: our experiences on indications and recent techniques. BioMed Res Int 2014;2014:373286. https://doi.org/10.1155/2014/373286.
[51] O'Sullivan NA, Kobayashi S, Ranka MP, Zaleski KL, Yaremchuk MJ, Bonassar LJ, Randolph MA. Adhesion and integration of tissue-engineered cartilage to porous polyethylene for composite ear reconstruction. J Biomed Mater Res B Appl Biomater 2015;103(5):983–91. https://doi.org/10.1002/jbm.b.33269.
[52] Bly RA, Bhrany AD, Murakami CS, Sie KC. Microtia reconstruction. Facial Plast Surg Clin North Am 2016;24(4):577–91. https://doi.org/10.1016/j.fsc.2016.06.011.
[53] Patel P, Brandstetter K. Solid implants in facial plastic surgery: potential complications and how to prevent them. Facial Plast Surg 2016;32:520–31. https://doi.org/10.1055/s-0036-1586497.
[54] Tark WH, Yoon IS, Rah DK, Park BY, Kim YO. Osteoconductivity of porous polyethylene in human skull. J Craniofac Surg 2012;23(1):78–80. https://doi.org/10.1097/SCS.0b013e318240c85d.
[55] Romano JJ, Iliff NT, Manson PN. Use of Medpor porous polyethylene implants in 140 patients with facial fractures. J Craniofac Surg 1993;4:142 7. https://doi.org/10.1097/00001665-199307000-00007.
[56] Vuyk HD. Augmentation mentoplasty with solid silicone. Clin Otolaryngol Allied Sci 1996;21(2):106–18. https://doi.org/10.1111/j.1365-2273.1996.tb01312.x.
[57] Gross EJ, Hamilton MM, Ackermann K, Perkins SW. Mersilene mesh chin augmentation. A 14-year experience. Arch Facial Plast Surg 1999;1(3):183–9. https://doi.org/10.1001/archfaci.1.3.183.
[58] Brandt MG, Moore CC. Implants in facial skeletal augmentation. Curr Opin Otolaryngol Head Neck Surg 2013;21(4):396–9. https://doi.org/10.1097/MOO.0b013e32836385d1.