

Predictable 3-D-face-reconstruction using facial and dental implants

author_Manfred Nilius, Germany

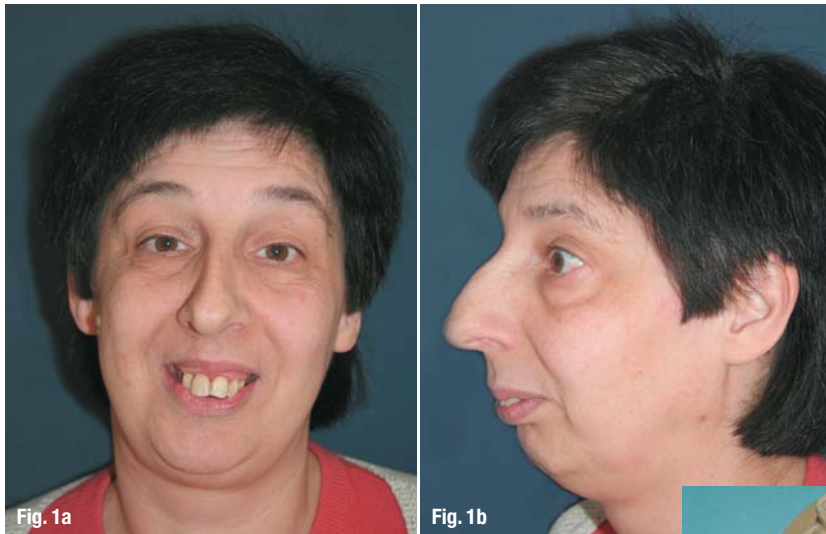

Fig. 1a-b_Front and semilateral view before surgery. Maxillary prognathism, retrogeny, gothic maxillary arch, labial protrusion of the incisors.

Fig. 2a-b_Plaster analysis.

Fig. 3_Nobel Speedy RP 12 mm.

Fig. 4a-b_Implant guided palatinal distractor (IGPD) for transverse distraction of the palate. The IGPD was adjusted beforehand and intraoperatively fixed on four implants using guided temporary abutments. Anterior gap for oral feeding.

Fig. 5_Lateral x-ray before operation.

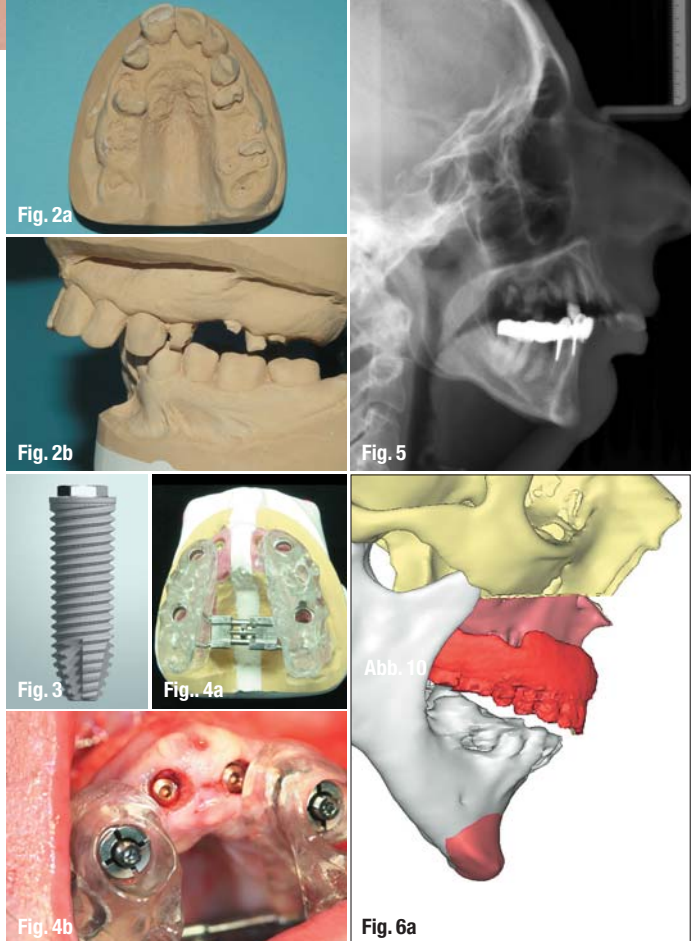
Fig. 6a-b_Exact planning for LeFort I osteotomy, palatinal split and volumetry of the chin was performed by CMF®-Software (Simplant Pro10.01; Platform V10.0.1.6).

_Abstract

Surgery of craniofacial deformities is a complex task that requires careful preoperative planning. In this field Nobel-Guide®-System made a great impact of predictable implantology. Using these for computer-aided surgery (CAS) the patient outcome of extreme dental and facial makeovers can be anticipated. The following case report shows new indications for dental implants by using Nobel-Guide®-System for fixation of a prefabricated "Implant Guided Palatinal Distractor" (IGPD) and for an implant bridge. Thus, embedding dental implantation in maxillofacial procedures like LeFort osteotomy, forced guided palatinal distraction, chin augmentation and septorhinoplasty can be performed in a single-step operation. Operation time and costs can be reduced.

_Introduction

With traditional two-dimensional preoperative work-up, the prediction of the postoperative appearance of the patient's face is limited. Today's surgery simulation systems do not anticipate soft tissue changes resulting from the alteration of underlying bones. Implant simulation programs do not realistically predict exact implant positions. Nobel-Guide®-System made a great impact on the field of predictable implantology and was used for exact implant positioning. Facial performance was planned by CMF®-module to visualize three-dimensional operation procedures and soft tissue movement in maxillofacial surgery.



Material and Methods/Case Report

Clinical situation before extreme facial makeover:

A 52 year old woman was referred to our clinic for treatment of temporomandibular joint disorders (TMJ) and for orthognathic surgery (Fig. 1a–b, 2a–b). The clinical investigation showed a large facial asymmetry including prognathism, mandibular retrogeny, lateral right deviated hook-long-nose including deviated nasal septum, naevus-cell-naevi on the right cheek, a missing chin and thus a reduced horizontal high of the lower facial third. The intraoral view demonstrated a

patient's head including Nobel-Guide®-System to fabricate an "Implant Guided Palatal Distractor" (IGPD) and the CMF®-module for skull surgery (Fig. 3–6). A physical model of the skull was created through computergenerated reconstruction using stereolithography on which planned surgery was simulated. Properties of the soft tissue between the skin and bone were simulated by an anatomy-based physical model (CMF®). The impact of the bone realignment formed by the surgery simulation then transferred to the tissue by photomapping (Figs. 1a, 1b, 2a, 2b).

Results

Clinical situation after dental and facial implantation:

Due to CT-analysis, computer based planning and the use of templates the dental implants were brought in very safe and quick. The implementation of the "Implant Guided Palatal Distractor" (IGPD) based on 8 implants was very simple, immediate functions on the implants without complications. The precise fixation of the prefabricated chin was uncomplicated. The functional oral rehabilitation, mastication and esthetic restoration—thus the oral and facial result two weeks later highly appreciated by the patient (Figs. 10a, 10b).

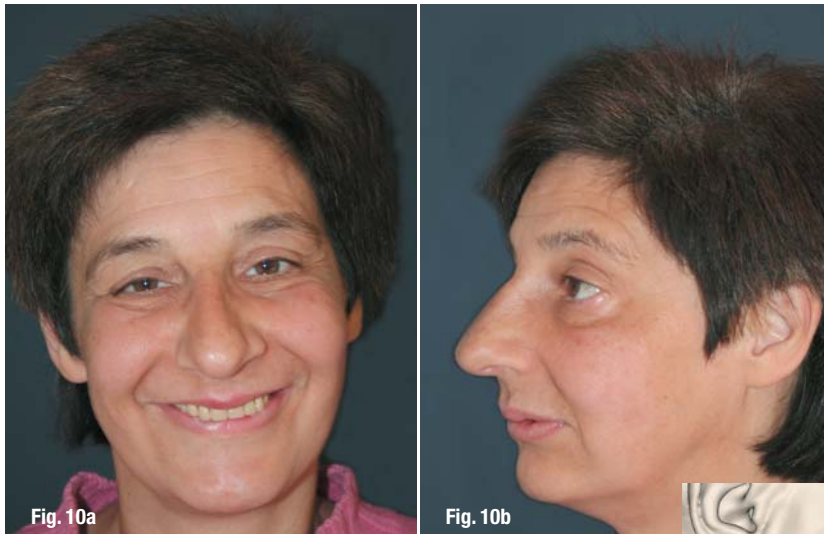

Fig. 10a

Fig. 10b

Fig. 7 Surgery was divided into the following seven steps.

7a Minimalinvasive implantation of 8 implants (NB Speedy Groovy RP 12 mm, punch technique) using the Nobel-Guide®-Template.

7b LeFort I osteotomy.

7c Sagittal split of the palate, palatal distraction (7 mm), immediate loading of the implants, temporary intermaxillary fixation using "IGPD".

7d Chin augmentation using a prefabricated chin (MEDPOR® Surgical Implants).

7e Transmaxillary and endonasal septorhinoplasty.

7f Dental rehabilitation with an implant bridge (2 weeks later).

Fig. 10a–b Front and semilateral view after surgery.

gummy-smile and every maxillary tooth decayed, labial protruded front teeth (overjet: 30 mm, overbite: 4 mm), deminished transversal extension of the palate and a gothic arch. Habits: Mandibular protrusion of 4 mm.

Treatment planning

After analyzing dental and facial deficits teeth extraction of the maxillary teeth was performed. Dental implantation was planned using Nobel-Guide®. Eight implants (NB Speedy Groovy RP 12 mm) were planned in position 016, 015, 013, 012, 022, 023, 025, 026. Properties of the soft tissue between the skin and bone were simulated by an anatomy-based virtual model CMF®-module.

Procedures

Surgical procedures were simulated by using a 3-D Scan of the

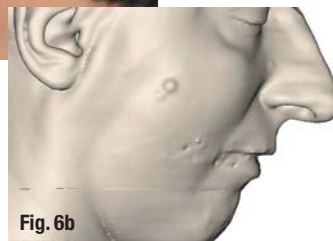

Fig. 6b

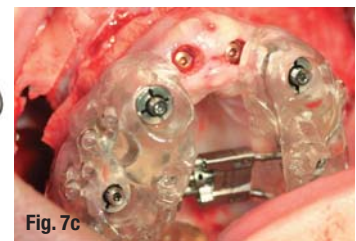


Fig. 7c

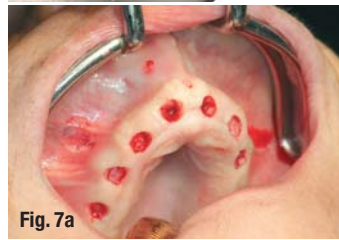


Fig. 7a

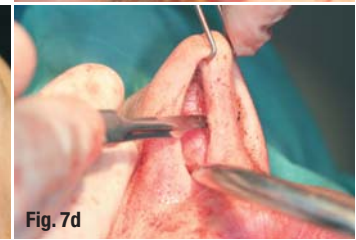

Fig. 7d

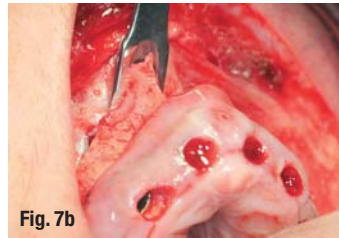


Fig. 7b

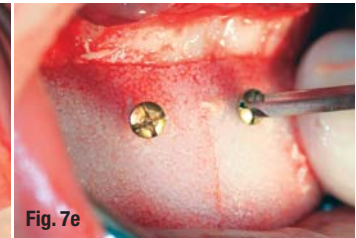


Fig. 7e

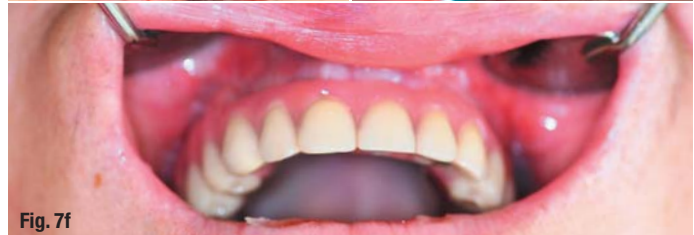

Fig. 7f

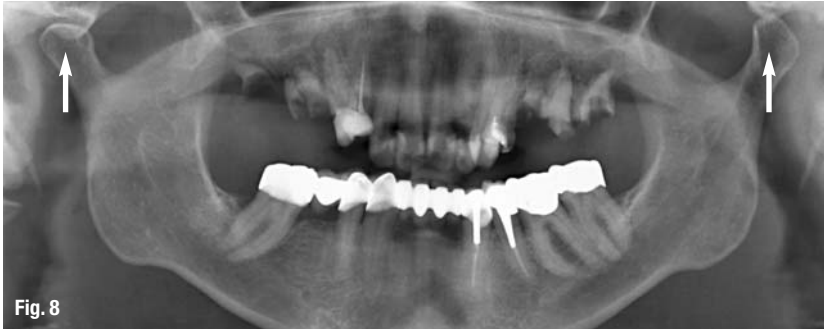

Fig. 8

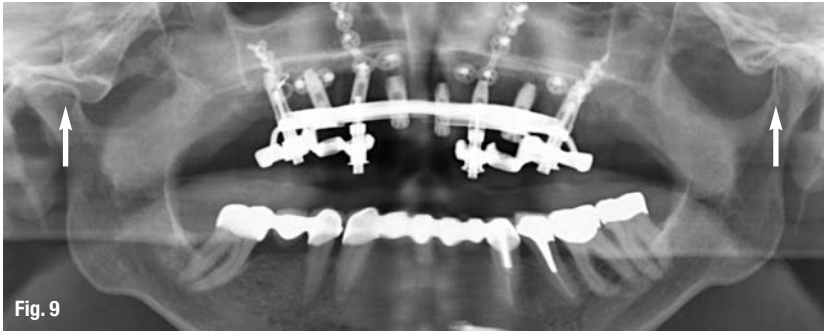


Fig. 9

Fig. 8 Preoperative orthopantomography (OPT). Decayed maxillary teeth and noncentric anterior position of the mandibular process due to protrusion.

Fig. 9 Postoperative OPT after implantation, immediate loading (IGPD), LeFort I osteotomy and chin augmentation. Centric position of the mandibular process.

Discussion

Because of their wide-ranging surgical impact, craniofacial operations require careful preoperative planning. The goal is not only to improve the functionality, but also to restore an esthetically pleasing face for patients with large facial deformities. Combining Nobel-Guide®-Systems for dental implantation with other modern CAS systems like CMF®-module for simulation of complex surgical procedures allows prediction of the patient's postoperative appearance. Prefabricated distractors (IGPD) or other

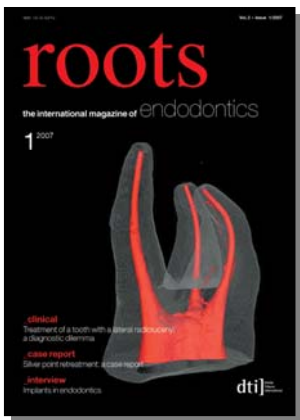
orthodontic templates can be implemented like common prosthodontic fixtures or teeth in the "Teeth-in-an-hour-Concept®". Comprising skin, tissue and skull data, CMF®-module allows a precise preoperative three-dimensional visualization of the patient's appearance after craniofacial surgery. The demonstrated case shows methods to give the surgeon the ability to work interactively with the patient skin and skull data and to simulate different surgical procedures to improve the planning process. For 15 years, facial implants have been used in plastic surgery for graftless defect restoration.

Especially in the field of facial renewals ready-made replacements can be planned with 3-D-Software and used easily to improve the esthetic look. The presented case report demonstrates the efficiency and strengths of this new approach. While many patients desire facial and not only dental solutions every dentist should know about the opportunities contemporary treatments can do for everyone of these patients.

| | |
|--|-----------------|
| _contact | implants |
| <p>Dr Dr Manfred Nilius</p> <p>Niliuslinik, Londoner Bogen 6 44269 Dortmund, Germany E-mail: info@niliuslinik.de Web: www.niliuslinik.de</p> | |

AD

For me, the specialist...



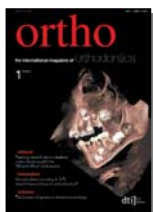Each magazine is \$99 (+ shipping) for a 2-year subscription.

To start your subscription please contact Lorrie Young at l.young@dental-tribune.com

roots the international magazine of endodontics



cosmetic dentistry beauty & science



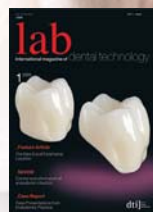ortho the international magazine of orthodontics



implants the international magazine of oral implantology



laser the international magazine of laser dentistry



lab the international magazine of dental technology



dti Dental Tribune International

Dental Tribune America, LLC
213 West 35th Street, Suite #801
NY 10001, New York, U.S.A.
Phone: +1.212.244.7181 • Fax: +1.212.244.7185
E-mail: l.young@dental-tribune.com